The Importance of Modified Budin Incidence in the Radiological Diagnosis in Patients with Aseptic Necrosis of the Femoral Head

ALEXANDRU PATRASCU[1,2], LILIANA SAVIN[1,2]*, DAN MIHAILESCU[1,2]*, CARMEN GREIEROSU[1,2], VICTOR GRIGORESCU[1,2], TEODOR ZLATE[1,2], LETITIA DOINA DUCEAC[3], LIVIU STAFIE[4], PAUL BOTEZ[1,2]

[1] Grigore T. Popa University of Medicine and Pharmacy, Faculty of Medicine, Department of Orthopaedics and Traumatology, 16 Universitatii Str., 700115, Iasi, Romania

[2] Clinical Rehabilitation Hospital, Orthopaedic Trauma Surgery Clinic, 14 Pantelimon Halipa Str., 700613, Iasi, Romania

[3] Emergency Hospital for Children Sf. Maria Faculty Apollonia, 62 Vasile Lupu Srt., 700309, Iasi, Romania

[4] Faculty Apollonia, Department of Public Health, 2-4 Vasile Conta Str., 700309, Iasi, Romania

This study included 56 patients who presented hip pain occurring spontaneously without any trauma history. A new radiological protocol was initiated for all the patients suspected of NACF. A pelvis, Dunlop profile and modified Budin at both hips scan was performed. In order to emphasize the effectiveness of the new radiological protocol, the following indicators were analyzed: the mobility of the affected hip, the radiological changes typical to the aseptic necrosis of the femoral head, the extension angle of the necrosis area on every incidence after Kerboul [1,2], the surface area covering the necrosis zone on every incidence and the coverage on every patient. The modified Budin profile has a greater diagnostic value for the early stages of NACF than the Dunlop profile and the radiography. The Budin incidence is important in order to differentiate stage III of NACF from stage IV by highlighting the degenerative changes in the acetabular cavity.

Keywords: necrosis of the femoral head, osteonecrosis, modified Budin incidence

In aseptic necrosis of the femoral head presented in the stage prior to the radiography on a simple X-ray, the sensitivity is relatively low and the dead bone can be seen normally, without any shaded area. However, radiography may be helpful to understand the overall structure of the surrounding area and can be used for imaging examination and monitoring the progress of the lesion with repeated examinations. The NACF staging is described by the radiographic findings, RMN or CT.

The anterior-posterior and lateral X-Ray, or the Dunlop profile are the base of the radiological examination for the diagnosis of osteonecrosis of the femoral head. On the anterior-posterior radiological examination, the osteonecrosis of the femoral head affects the anterior-superior portion and the lesion is usually overlapped with the acetabulum. However, in the lateral portion of the Dunlop profile, the contour of the femoral lesion can be seen.

In the state prior to radiography of NACF, the radiography can be seen normal (stage I ARCO even if there is an histopahtological osteonecrosis. To identify osteonecrosis in this stage, RMN can be useful. After this, the mottled and radiodensity areas are visible on the subchondral portion of the anterior side of the femoral head (ARCO stage II). However, abnormal density of this area must be distinguished from normal heterogeneous density, caused by the overlapped shadow on the acetabular anterior and posterior columns. Increasing the density of the femoral head shows revascularization and bone repair.

Experimental part

The study is prospective and observational. We evaluated 56 patients hospitalized with a diagnosis of aseptic necrosis of the femoral head according to the Ficat Arlet staging [3-6] which presented hip pain without trauma history. The study was conducted in the Department of Orthopedics - Traumatology, Rehabilitation Hospital, Iasi.

Data was collected through clinical and radiological examination of both hips in patients in the study and obtaining the indicators tracked in QCAD program where all the radiological incidences were loaded.

The x-ray imaging examination consisting of the pelvis, front hip, Dunlop profile and modified Budin profile [7].

Study protocol

The study included 56 patients who presented during March-July 2017 having hip pain that occurred spontaneously without trauma history. A new radiological protocol was initiated for all patients suspected of NACF. Pelvis Dunlop profile and modified Budin scans were performed on both hips. In order to emphasize the effectiveness of the new radiological protocol, the following indicators were analyzed: the mobility of the affected hip, the radiological changes typical to aseptic necrosis of the femoral head, the extension angle of the area of necrosis on each incidence after Kerboul [1, 2], the surface of area of the coverage of necrosis on each incidence and the coverage on every incidence on each patient. The mobile device for radiology RAD G100 for imaging examination is used in the radiology department of the hospital (fig.1).

Fig.1 Mobile radiology device

* email: lilisavin@yahoo.com; danmih_86@yahoo.com

Protocol for existing aseptic necrosis of the femoral head involves performing a hip X-ray to investigate, hip profile and Dunlop incidence.

The new protocol included in this study is the introduction of a particular incidence, modified Budin, [7] used in the hip, in order to highlight the maximum area of the port where the necrosis zone develops in early stages of NACF.

Collimator size

No radiological film is used, the collimator size is 24/30cm long. The inferior edge exceeds the ischium and the superior edge exceeds the anterior-superior iliac crest. The inner edge exceeds the coxofemural studied joint and the external edge exceeds the middle third of the femoral shaft.

Patient positioning

The patient is positioned on a chair seat with special lift for the femoral axis to be parallel to the ground, with the knee flexed 900 to the tight (fig.2) and 450 to the median plane (fig. 3).

Fig.2. Patient positioning within Budin incidence, lateral and superior view

Fig.3. Budin patient positioning within a lateral view

The ventral dose is perpendicular to the sensor and enters the flod situated on the front of the external hip formed of thigh and buttock.

The distance between the focus and the film is 150cm.

The radio-graphical landmarks of the modified Budin incidence.

The special modified Budin incidence is an obturator incidence used by other authors [7-10] for calculation of the femoral anteversion which is and important ATS feature. In this particular incidence we emphasize the portion of the maximum area in the anterolateral femoral

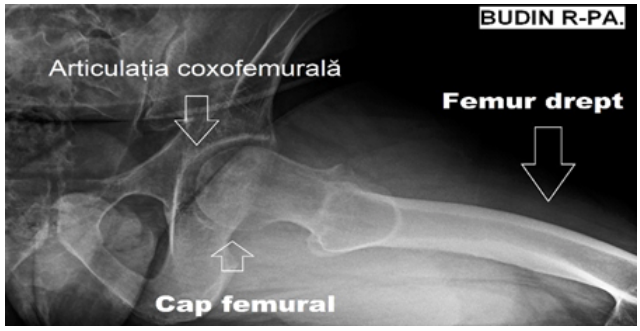

Fig.4. Modified Budin incidence of the right hip

head and the posterior-superior femoral head (fig.4) thing that is essential to the early diagnosis of the necrosis of the femoral head. Also through this incidence we emphasize the stage of affection of the cotyloid cavity which can help the surgeon in choosing the therapeutic option.

Indicators followed in the study:

To achieve the objective of this study, we followed these indicators:

- the extension angle of the necrosis area on each occasion;
- the area of the necrosis zone for each occasion;
- the surface area of necrosis in each occasion.

To obtain the tracked indicators we used the QCAD program to load all the radiological incidences.

The calculation of the extension angle of the necrosis area:

To calculate the extension angle of the necrosis area we used the Kerboul method [1,2] applied on every radiological incidence with the help of the QCAD program.

After loading the X-ray, the deepest point of the area of necrosis along with the two points of the subchondral area to the coxfemural joint area of the head which delimits the area of necrosis of the head (fig. 5). After that, using the trace function of the lines, three points go together and then the angle formed by the two lines is measured using the function of the angle calculation. This is repeated for each incidence (front, Dunlop profile, modified Budin profile) on each patient (fig.6).

Calculating the extension area of the necrotic zone

To calculate the extension area of the necrotic zone, the loading operation of each incidence on each patient is repeated and using the QCAD function, all the points delimiting the area of necrosis are selected and then generate the calculation of the area zone. Its value appears at the bottom of the image or next to the necrotic zone on the imported image (fig.7).

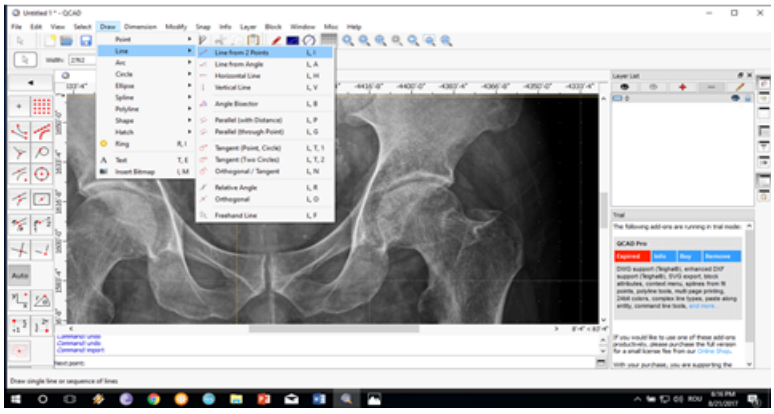

Fig.5. Marking of the points on the edge of necrosis

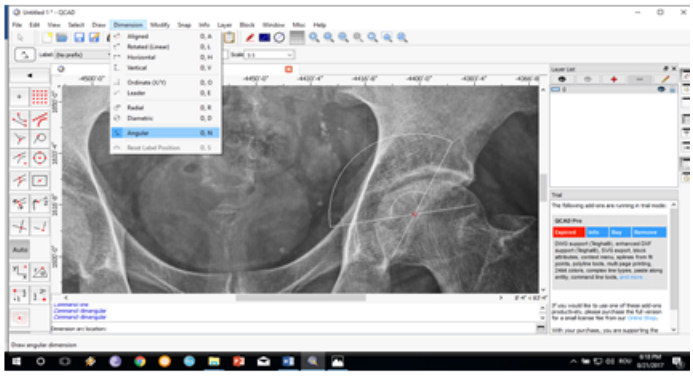

Fig.6. The calculation of the extension angle of the necrosis area

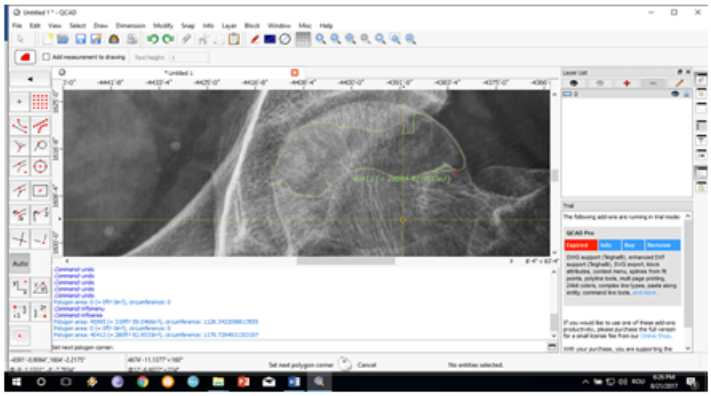

Fig.7. Calculating the area of extension of the necrosis of the femoral head

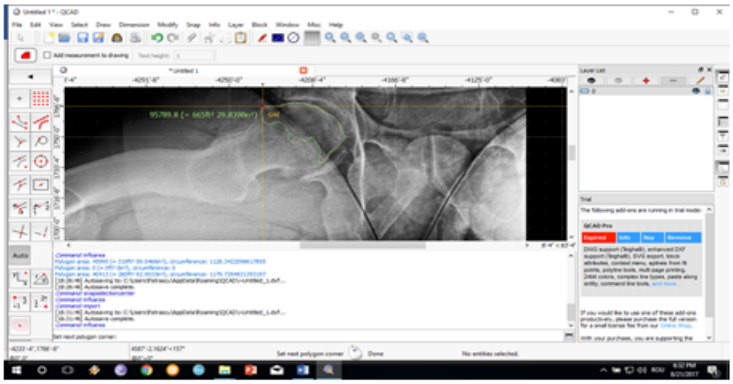

Fig.8. Calculation of the circumference of the necrosis of the head

Calculating the extension circumference of the necrotic zone

The formation function of the polygonal area is selected and through multiple points located at the its edge, the necrotic zone it's separated. After its separation, all the three points unite and they result in the circumference of the desired zone. Its value appears next to the selected area (fig.8).

Results and discussions

The extension angles of the necrotic zone were measured along with the area of necrosis zone and the surface of the necrotic zone, on a number of 56 patients with aseptic necrosis of the femoral head, using three methods: face radiograph, Dunlop profile and modified Budin profile. The average values of these indicators were compared between the groups of patients with stage 0, I and II together, stage III and IV, using the *t* test for independent samples in the descriptive statistics using the grouping variable, stage of disease and bearing in mind that those differences which are $p<0.05$ are significant.

The average value of the extension angle of the necrotic area measured on radiographs was significantly higher in patients with stage III (129.75) and IV (146.11) compared to 0.00 at stage 0, I and II together, $p<0.0000001$. Between stage III and IV, the difference was not found to be statistically significant, although the mean was higher in stage IV (146.11 to 129.75, $p = 0.06$) (table 1).

The average angle of the extension angle of the necrosis area measured on Dunlop profile radiographs was significantly higher in patients with stage III (78.90 to 141.25 as compared to the stages 0, I and II in combination, $p = 0.0004$) and IV (152.33) compared to 78.90 at stage 0, I and II in combination, $p = 0.00005$). Between stage III and IV, the difference was not found to be statistically significant, although the mean was higher in stage IV (152.33 to 141.25, $p = 0.13$) (table 1).

The average value of the extension angle of the necrosis area on modified Budin profile had no statistically significant differences in patients with stage III compared to patients with stage 0, I and II aggregate (as compared to 158,00 149.30, $p = 0.28$). Compared with stage IV, the average value was significantly higher in stage IV (172.56 to 149.30 to stage 0, I and II in combination, $p = 0.007$). Also, the mean value was significantly higher in patients with stage IV compared with stage III (158.00 to 172.56 as compared with those with stage III $p = 0.001$) (table 1).

Compared to stage 0, I and II cumulative, the average area of the necrosis zone measured within the basin incidence, according to the stage of the disease was significantly higher in patients with stage III (40321.42) and IV (90713.96) 8025.31 compared with the stage 0, I and II together, $p<0.0000001$. Also, the mean in stage IV was significantly higher compared to stage III (90713.96 to 40321.42 at stage III, $p<0.0000001$) (table 2).

Compared stages	Average 1	Average 2	t	gl	p
Anterior rgf					
(0+I+II) with III	0.00	**129.75**	35.249	34	**<0.0000001**
(0+I+II) with IV	0.00	**146.11**	22.086	36	**<0.0000001**
III with IV	129.75	146.11	1.953	32	0.06
Dunlop profile					
(0+I+II) with III	75.90	**141.25**	3.966	34	**0.0004**
(0+I+II) with IV	75.90	**152.33**	4.639	36	**0.00005**
III with IV	141.25	152.33	1.552	32	0.13
Budin profile					
(0+I+II) with III	149.30	158.00	1.097	34	0.28
(0+I+II) with IV	149.30	**172.56**	2.887	36	**0.007**
III with IV	158.00	**172.56**	3.476	32	**0.001**

Table 1
COMPARISONS OF THE EXTENSION ANGLE OF THE NECROTIC AREA MEASURED ON ANTERIOR, DUNLOP AND BUDIN PROFILE RADIOGRAPHS, DEPENDING ON THE STAGE OF THE DISEASE

Compared stages	Average 1	Average 2	t	gl	p
Anterior rgf					
(0+I+II) with III	8025.31	40321.42	12.081	34	**<0.0000001**
(0+I+II) with IV	8025.31	90713.96	21.385	36	**<0.0000001**
III with IV	40321.42	90713.96	14.441	32	**<0.0000001**
Dunlop profile					
(0+I+II) with III	12647.19	58259.94	9.279	34	**<0.0000001**
(0+I+II) with IV	12647.19	112749.3	25.158	36	**<0.0000001**
III with IV	58259.94	112749.3	10.256	32	**<0.0000001**
Budin profile					
(0+I+II) with III	90251.02	148053.3	3.362	34	**0.002**
(0+I+II) with IV	90251.02	189427.8	8.327	36	**<0.0000001**
III with IV	148053.3	189427.8	2.117	32	**0.04**

Table 2
COMPARISONS OF THE AREA OF NECROSIS ZONE MEASURED WITHIN THE ANTERIOR, DUNLOP AND BUDIN PROFILE ACCORDING TO THE STAGE OF THE DISEASE

The average area of the necrotic zone measured on Dunlop profile, depending on the stage of the disease was significantly higher in patients with stage III compared with stage 0, I and II cumulative (58259.94 to 12647.19 at stage 0, I and II together, p <0.0000001) and to those with stage IV (112749.3 12647.19 compared with the stage 0, I and II together, p <0.0000001). Also, the average area of necrosis zone on Dunlop profile was significantly higher in patients with stage III versus stage IV (112749.3 58259.94 compared with those with stage III p <0.0000001) (table 2).

The average area of necrotic zone measured on the modified Budin profile, depending on the stage of the disease was significantly higher in patients with stage III compared with stage 0, I and II cumulative (90251.02 148053.3 to the stages 0, I and II cumulative, p = 0.002) and in patients with stage IV (189427.8 90251.02 compared with the stage 0, I and II together, p <0.0000001). Also, the average area of necrotic zone measured on the modified Budin profile was significantly higher in patients with stage III versus stage IV (189,427.8 148,053.3 compared with those with stage III, p = 0.04) [table 2].

Compared with the stage 0, I and II together, the average value of the surface area of the necrotic zone measured within the basin incidence, according to the stage of the disease was significantly higher in patients with stage III (897.20) and IV (1198.34) 255.08 compared to the stages 0, I and II together, p <0.0000001. Also, the mean in stage IV was significantly higher compared to stage III (1198.34 897.20 to stage III, p = 0.000003) (table 3).

The average value of the surface area of necrosis measured on Dunlop profile, depending on the stage of the disease. was significantly higher in patients with stage III

Compared stages	Average 1	Average 2	t	gl	p
Anterior rgf					
(0+I+II) with III	255.08	897.20	7.688	34	**<0.0000001**
(0+I+II) with IV	255.08	1198.34	10.886	36	**<0.0000001**
III with IV	897.20	1198.34	5.685	32	**0.000003**
Dunlop					
(0+I+II) with III	386.80	1015.64	7.192	34	**<0.0000001**
(0+I+II) with IV	386.80	1404.32	11.859	36	**<0.0000001**
III with IV	1015.64	1404.32	8.409	32	**<0.0000001**
Budin					
(0+I+II) with III	1180.12	1755.22	4.221	34	**0.0002**
(0+I+II) with IV	1180.12	2051.79	8.292	36	**<0.0000001**
III with IV	1755.22	2051.79	1.946	32	0.06

Table 3
COMPARISONS OF THE SURFACE AREA OF NECROSIS MEASURED ON THE ANTERIOR, DUNLOP AND BUDIN PROFILE, DEPENDING ON THE STAGE OF THE DISEASE

Table 4
COMPARISON OF THE AVERAGE VALUES OF THE EXTENSION ANGLE OF THE NECROTIC ZONE IN PATIENTS WITH STAGE 0, I AND II CUMULATIVE, USING THE THREE METHODS OF MEASUREMENT

Compared methods	Average 1	Average 2	p
1 with 2	0.00	75.90	**<0.00001**
1 with 3	0.00	149.30	**<0.00001**
2 with 3	75.90	149.30	**0.0001**

Legend: 1=face radiography; 2= Dunlop profile; 3=modified Budin profile

Table 5
COMPARISON OF THE AVERAGE VALUES OF THE EXTENSION ANGLE OF THE NECROTIC AREA IN PATIENTS WITH STAGE III, USING THE THREE METHODS OF MEASUREMENT

Compared methods	Average 1	Average 2	p
1 with 2	129.75	141.25	**0.025**
1 with 3	129.75	158.00	**<0.00001**
2 with 3	141.25	158.00	**<0.00001**

Legend: 1=face radiography; 2= Dunlop profile; 3=modified Budinprofile

compared with stage 0, I and II cumulative (386.8 to 1015.64 at stage 0, I and II together, p <0.0000001) and to those with stage IV (386.8 1404.32 compared with the stage 0, I and II together, p <0.0000001). Also, the average value of the surface area of the profile Dunlop necrosis was significantly higher in patients with stage III versus stage IV (1404.32 1015.64 compared to those with stage III p <0.0000001) [table 3].

The average value of the surface area of necrosis measured on the modified Budin profile, depending on the stage of the disease was significantly higher in patients with stage III compared with stage 0, I and II cumulative (1755.22 to 1180.12 at stage 0, I and II cumulative, p = 0.0002) and those with stage IV (2051.79 1180.12 compared with the stage 0, I and II together, p <0.0000001). The average value of the surface area of necrosis measured on the modified Budin profile, did not differentiate significantly in patients with stage III to stage IV patients, stage IV although the average value was higher (1755.22 to stage III, as compared to 2051.79 patients with stage IV, p = 0.06) (table 3).

Moving forward, in order to highlight the differences between the three methods of measurement, we compared the average values of the extension angles of the necrotic zone, of the area of the surface of necrotic zone and the surface of the necrotic zone on stages, at the three measurement methods.

The average value of the extension angle of the necrotic zone in patients with stage 0, I and II cumulative, has been shown to be significantly changed largely on Budin profile (149.3, compared to 75.9 measured on the profile Dunlop, p = 0.0001, and to x-ray measured to 0.00, p <0.00001). In turn, the angle measured on the Dunlop profile was significantly higher than that measured on the radiography of the face (75.9 to 0.00, p <0.00001) (table 4).

The average value of the extension angle of the necrotic area in patients with stage III has been shown to be significantly changed largely on Budin profile (158, compared to the measured x-ray to 129.75, p <0.00001, and from the measured Dunlop profile 141.25, p <0.00001). In turn, the average value of the measured angle in Dunlop profile was significantly higher than the one measured on the radiography of the face (141.25 to 129.75, p = 0.025) (table 5).

The average value of the extension angle of the necrosis area in patients with stage IV has been shown to be significantly changed largely on Budin profile (172.56 compared to the measured x-ray to 146.11, p = 0.002, and the measured profile 152.33 Dunlop, p = 0.009). The average value of the measured angle on Dunlop profile was not significantly different compared to the measured x-ray (152.33 to 146.11 to the x-ray, p = 0.51) (table 6).

The average area of the necrotic zone in patients with stage 0, I and II cumulative has been shown to be significantly higher in modified Budin profile (90251.02 8025.31 compared to the measured x-ray, p <0.0001, 12647.19 and Dunlop profile, p <0.00001). The average area of the necrotic zone as measured by Dunlop profile was not significantly higher compared to the x-ray (8025.31

to 12647.19 x-ray to the front, p = 0.19), probably due to the inter-individual variability (very large standard deviation in the group of patients that was measured using the radiography) (table 7).

The average value of the area of the necrotic zone in patients with stage III, has been shown to be significantly higher in modified Budin profile (148053.3 40321.42 compared to the x-ray, p <0.00001, and to 58259.94 Dunlop profile, p <0.00001). In turn, the average value of the area of the necrotic zone measured by Dunlop profile was significantly higher than the one measured on the radiography of the face (58259.94 to 40321.42, p = 0.0004) (table 8).

The average value of the area of the necrotic zone in patients with stage IV, has been shown to be significantly higher in modified Budin profile (189427.8 90713.96 compared to the x-ray, p <0.00001, and to of 112,749.3 measured on Dunlop profile, p <0.00001). The average value of the area of the necrotic zone measured by Dunlop profile in turn, was significantly higher compared to the x-ray (X-ray 112,749.3 to the present 90713.96, p <0.00001) (table 9).

The average value of the surface of the necrotic zone in patients with stage 0, I and II has been shown to be significantly higher in modified Budin profile (1180.12 255.08 compared to the x-ray, p <0.00001, and to the measured Dunlop profile 386.80, p <0.00001). The average value of the surface of the necrotic zone measured on Dunlop profile was not significantly higher than the one measured on the radiography of the face (386.8 to 255.08, p = 0.21) (table 10).

The average value of the surface of the necrotic zone in patients with stage III, has been shown to be significantly higher in modified Budin profile (1755.22 compared to the x-ray 897.2, p <0.00001, and to 1015.64 Dunlop profile, p <0.00001). In turn, the average value of the surface area of the necrotic zone measured on Dunlop profile was significantly higher compared to the measured x-ray (1015.64 to 897.20, p = 0.004) (table 11).

Table 6

COMPARISON OF THE AVERAGE VALUES OF THE EXTENSION ANGLE OF THE NECROSIS AREA IN PATIENTS WITH STAGE IV, USING THE THREE METHODS OF MEASUREMENT

Compared methods	Average 1	Average 2	p
1 with 2	146.11	152.33	0.51
1 with 3	146.11	172.56	**0.002**
2 with 3	152.33	172.56	**0.009**

Legend: 1=face radiography; 2= Dunlop profile; 3=modified Budin profile

Table 7

COMPARISON OF THE AVERAGE AREA OF THE NECROTIC ZONE IN PATIENTS WITH STAGE 0, I AND II CUMULATIVE, USING THE THREE METHODS OF MEASUREMENT.

Compared methods	Average 1	Average 2	p
1 with 2	8025.31	12647.19	0.19
1 with 3	8025.31	90251.02	**<0.00001**
2 with 3	12647.19	90251.02	**<0.00001**

Legend: 1=face radiography; 2= Dunlop profile; 3=modified Budin profile

Table 8

COMPARISON OF THE AVERAGE VALUE OF THE AREA OF THE NECROTIC ZONE IN PATIENTS WITH STAGE III, USING THE THREE METHODS OF MEASUREMENT

Compared methods	Average 1	Average 2	p
1 with 2	40321.42	58259.94	**0.0004**
1 with 3	40321.42	148053.3	**<0.00001**
2 with 3	58259.94	148053.3	**<0.00001**

Legend: 1=face radiography; 2= Dunlop profile; 3=modified Budin profile

Table 9

COMPARISON OF THE AVERAGE VALUE OF THE AREA OF THE NECROTIC ZONE IN PATIENTS WITH STAGE IV, USING THE THREE METHODS OF MEASUREMENT

Compared methods	Average 1	Average 2	p
1 with 2	90713.96	112749.3	**<0.00001**
1 with 3	90713.96	189427.8	**<0.00001**
2 with 3	112749.3	189427.8	**<0.00001**

Legend: 1=face radiography; 2= Dunlop profile; 3=modified Budin profile

Table 10

COMPARISON OF THE AVERAGE VALUE OF THE SURFACE OF THE NECROTIC ZONE IN PATIENTS WITH STAGE 0, I AND II, USING THE THREE METHODS OF MEASUREMENT

Compared methods	Average 1	Average 2	p
1 with 2	255.08	386.80	0.21
1 with 3	255.08	1180.12	**<0.00001**
2 with 3	386.80	1180.12	**<0.00001**

Legend: 1=face radiography; 2= Dunlop profile; 3=modified Budin profile

Table 11

COMPARISON OF THE AVERAGE VALUE OF THE SURFACE OF THE NECROTIC ZONE IN PATIENTS WITH STAGE III, USING THE THREE METHODS OF MEASUREMENT

Compared methods	Average 1	Average 2	p
1 with 2	897.20	1015.64	**0.004**
1 with 3	897.20	1755.22	**<0.00001**
2 with 3	1015.64	1755.22	**<0.00001**

Legend: 1=face radiography; 2= Dunlop profile; 3=modified Budin profile

Table 12

COMPARISON OF THE AVERAGE VALUE OF THE SURFACE OF THE NECROTIC ZONE IN PATIENTS WITH STAGE IV, USING THE THREE METHODS OF MEASUREMENT

Compared methods	Average 1	Average 2	p
1 with 2	1198.34	**1404.32**	**0.001**
1 with 3	1198.34	**2051.79**	**<0.00001**
2 with 3	1404.32	**2051.79**	**<0.00001**

Legend: 1=face radiography; 2= Dunlop profile; 3=modified Budin profile

The average value of the surface of the necrotic zone in patients with stage IV has been shown to be significantly higher in modified Budin profile (2051.79 1198.34 compared to the measured x-ray, p <0.00001, and to 1404.32 measured Dunlop profile, p <0.00001). The average value of the surface area of necrotic zone measured on the Dunlop profile was significantly higher compared to the measured x-ray (X-ray 1404.32 to 1198.34 on the x-ray, p = 0.001) (table 12).

Conclusions

- The special modified incidence is an important radiological investigation in aseptic necrosis of the femoral head.
- The modified Budin profile has a greater diagnostic value in the early stages of NACF than Dunlop profile and radiography.
- The Budin incidence has an importance worth taking into account on the differentiation of stage III from stage IV NACF by highlighting the degenerative changes in the cotyloid cavity.

Reference

1.ARLET J, FICAT RP., Rev Rhum, 1964, 31:257–64.
2.KERBOUL M, THOMINE J, POSTEL M, MERLE D'AUBIGNE R. J Bone Joint Surg Br, 1974, 56:291–6.
3.STEINBERG ME. Tech Orthop, 2001, 16(1):6–15.
4.STEINBERG ME, STEINBERG DR. Orthop Clin North Am, 2004, 35:273–83.
5.ARLET J, FICAT RP., Rev Rhum, 1964, 31:257–64.
6.FICAT RP, ARLET J., Ischemia and necrosis of bone. Baltimore: Williams and Wilkins, 1980, p. 53–74.
7.BOISSONNEAULT A. R, TAKAFUMI HIRANAKA, ROBERSON J. R, BRADBURY T. L., The Journal Of Arthroplasty, 2017, 32:1018-1023.
8.RIPPSTEIN J., *Z* Orthop Ihre Grenzgeb, 1955,86:345.
9.BUDIN E, CHANDLER E., Radiology, 1957, 69:209.
10.LEE YK, KIM TY, HA YC, ET AL. Bone Joint J, 2013, 95-B:877.

Manuscript received: 4.10.2017